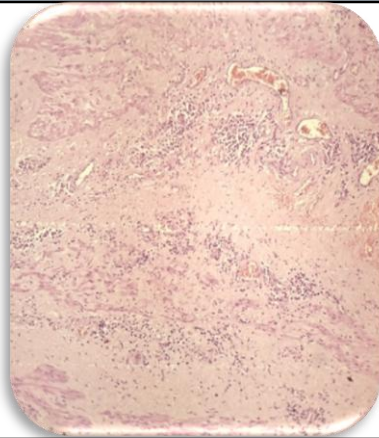


Patient Name	Mr. VIKASH SAINI-21543	Client Name	Pushpanjali Hospital	Specimen Received	14/12/2018
Age/Sex	32/M		(Rewari)	Specimen Type	Tissue
Patient ID	011812140188	Client Code	MolQ1789CM	Collection Date	14/12/2018
Specimen ID	MOLQ/B-1397/18	Ref. Doctor	DR.KULDEEP	Report Date	17/12/2018

SURGICAL PATHOLOGY REPORT
HEMORRHOIDS

DIAGNOSIS

HEMORRHOIDS



SPECIMEN
Hemorrhoids

GROSS
Received 1x2 cm greyish white tissue piece

Microscopy

- Section examined shows squamous lining epithelium with round nucleus . Deeper tissue shows large number of blood vessels, inflammatory cells and fibro collagenous tissue.

Note : All biopsy specimen will be stored for 15 (fifteen)days, block and slides for 5(five) years only from the time of receipt at the laboratory. No request ,for any of the above ,will be entertained after the due date.

Reference

- Rosai and Ackerman's Surgical Pathology.
- Modern Surgical Pathology.

Gulshan Yadav, MD
Consultant Pathologist