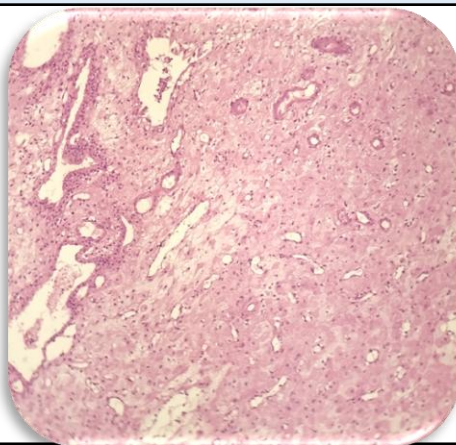


Patient Name	Mrs. GUDDI DEVI	Client Name	Ashtha Path Lab-B	Specimen Received	14/12/2018
Age/Sex	28 Years/Female	Client Code		Specimen Type	Tissue
Patient ID	011812140163			Collection Date	14/12/2018
Specimen ID	MOLQ/B-1398/18			Report Date	17/12/2018

SURGICAL PATHOLOGY REPORT

ENDOMETRIUM

MOLAR PREGNANCY



SPECIMEN

Endometrium

GROSS

Received multiple greyish white tissue piece.

Microscopy

1. Section examined shows decidual cells, trophoblastic cells with hydrophilic changes.

Note : All biopsy specimen will be stored for 15 (fifteen) days, block and slides for 5 (five) years only from the time of receipt at the laboratory. No request for any of the above, will be entertained after the due date.

Reference

- i) Rosai and Ackerman's Surgical Pathology.
- ii) Modern Surgical Pathology.

A handwritten signature in black ink, appearing to read 'Gulshan', written over a light blue rectangular background.

Gulshan Yadav, MD
Consultant Pathologist