

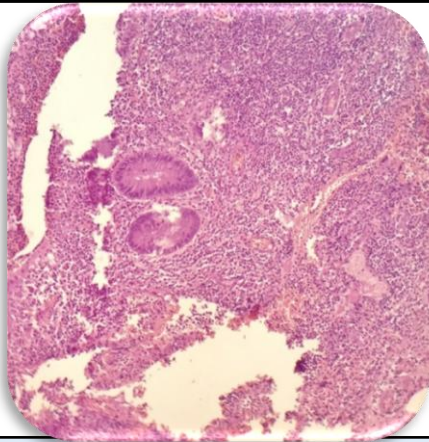
<b>Patient Name</b>	<b>Mrs. SUMITRA</b>	<b>Client Name</b>	Shri Balaji Multispeciality	<b>Specimen Received</b>	13/12/2018
<b>Age/Sex</b>	36 Years/Female		Hospital-Gurgaon	<b>Specimen Type</b>	Tissue
<b>Patient ID</b>	011812130200	<b>Client Code</b>	MolQ1269CM	<b>Collection Date</b>	13/12/2018
<b>Specimen ID</b>	MOLQ/B-1393/18	<b>Ref. Doctor</b>		<b>Report Date</b>	15/12/2018

## SURGICAL PATHOLOGY REPORT

### APPENDIX.

#### DIAGNOSIS

**ACUTE APPENDICITIS.**



#### SPECIMEN

Appendix.

#### GROSS

Received 5x0.5cm long appendix. Cut section shows fecolith

#### Microscopy

1. Section examined shows lymphoid follicles with ulcerative mucosa.
2. Deeper tissue shows inflammatory cells.

**Note :** All biopsy specimen will be stored for 15 (fifteen) days, block and slides for 5 (five) years only from the time of receipt at the laboratory. No request, for any of the above, will be entertained after the due date.

#### Reference

- i) Rosai and Ackerman's Surgical Pathology.
- ii) Modern Surgical Pathology.

**Gulshan Yadav, MD**  
Consultant Pathologist