

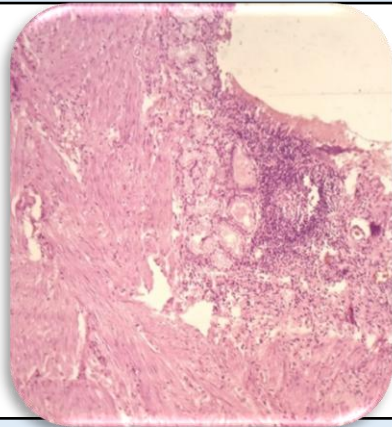
| | | | | | |
|---------------------|----------------|--------------------|------------------------------|--------------------------|------------|
| Patient Name | Mrs. KHURSHA | Client Name | New Unique Diagnostic Center | Specimen Received | 13/12/2018 |
| Age/Sex | 70/F | | Jammu & Kashmir | Specimen Type | Tissue |
| Patient ID | 011812130015 | Client Code | MolQ1833P | Collection Date | 13/12/2018 |
| Specimen ID | MOLQ/B-1389/18 | Ref. Doctor | | Report Date | 14/12/2018 |

SURGICAL PATHOLOGY REPORT

GALL BLADDER.

DIAGNOSIS

CHOLECYSTITIS AND CHOLELITHIASIS.



SPECIMEN

Gall Bladder.

GROSS

Received 6.2x3.2cm long gallbladder all ready cut open with tiny stones.

Microscopy

1. Section examined shows ulcerative mucosa and rokitansky aschoff sinus with fibrocollagenous tissue and inflammatory cells .

Note : All biopsy specimen will be stored for 15 (fifteen)days, block and slides for 5(five) years only from the time of receipt at the laboratory. No request ,for any of the above ,will be entertained after the due date.

Reference

- i) Rosai and Ackerman's Surgical Pathology.
- ii) Modern Surgical Pathology.

Gulshan Yadav, MD
Consultant Pathologist