

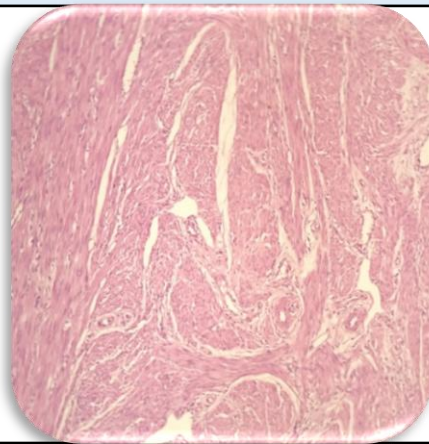
Patient Name	Mrs. MAHENDARI	Client Name	Civil Hospital-P	Specimen Received	10/12/2018
Age/Sex	40/F		Gurgaon	Specimen Type	Tissue
Patient ID	011812100196	Client Code	MolQ1681P	Collection Date	10/12/2018
Specimen ID	MOLQ/B-1364/18	Ref. Doctor	Dr. ALKA SINGH	Report Date	13/12/2018

SURGICAL PATHOLOGY REPORT

Uterus with polyp

DIAGNOSIS

CERVICAL POLYP



SPECIMEN

Uterus with polyp

GROSS

Received 10.5x5.2cm uterus with cervix. Cut section shows 3x1.8cm endocervical polyp.

Microscopy

1. Section examined shows
2. Endometrium with proliferative phase.
3. Myometrium with muscle bundle.
4. Cervix with mononuclear inflammatory cells.
5. Polyp shows endocervical cells with ectocervix and large number of inflammatory cells with keratinization.

Note : All biopsy specimen will be stored for 15 (fifteen)days, block and slides for 5(five) years only from the time of receipt at the laboratory. No request ,for any of the above ,will be entertained after the due date.

Reference

- i) Rosai and Ackerman's Surgical Pathology.
- ii) Modern Surgical Pathology.

Gulshan Yadav, MD
Consultant Pathologist