

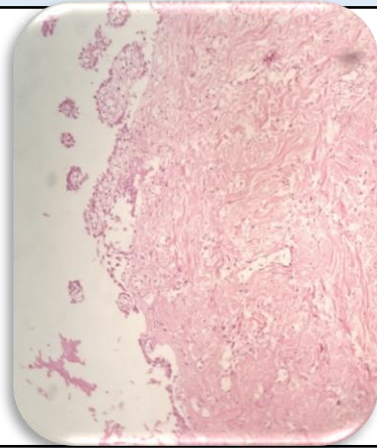
<b>Patient Name</b>	Ms RAHSUNI	<b>Client Name</b>	Jishan Path Lab, Sohna	<b>Specimen Received</b>	07/12/2018
<b>Age/Sex</b>	22/f	<b>Client Code</b>		<b>Specimen Type</b>	Tissue
<b>Patient ID</b>	011812070156	<b>Ref. Doctor</b>		<b>Collection Date</b>	07/12/2018
<b>Specimen ID</b>	MOLQ/B-1358-18			<b>Report Date</b>	11/12/2018

## SURGICAL PATHOLOGY REPORT

### Growth in Buccal Mucosa

#### DIAGNOSIS

### MUCOUS RETENTION CYST



#### SPECIMEN

Growth in Buccal Mucosa

#### GROSSING

Received tiny greyish white tissue piece.

#### Microscopy

1. Section examined shows squamous lining epithelium with round to oval nucleus with mucin pooling.
2. Connective tissue stroma shows fibrocollagenous tissue, thick bundles of collagen fibers and few inflammatory cells chiefly composed of lymphocytes and plasma cells.

**Note :** All biopsy specimen will be stored for 15 (fifteen) days, block and slides for 5 (five) years only from the time of receipt at the laboratory. No request for any of the above will be entertained after the due date.

#### Reference

- i) Rosai and Ackerman's Surgical Pathology.
- ii) Modern Surgical Pathology
- iii) Shafers, 7<sup>th</sup> Edition

**Tina Bhardwaj, MDS**  
Consultant Oral Histopathologist

**Gulshan Yadav, MD**  
Consultant Pathologist