

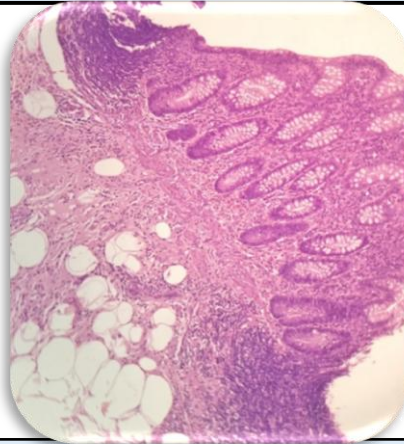
|                     |                   |                    |                    |                          |            |
|---------------------|-------------------|--------------------|--------------------|--------------------------|------------|
| <b>Patient Name</b> | <b>Mr. BHUPAL</b> | <b>Client Name</b> | Brijanand Path Lab | <b>Specimen Received</b> | 06/12/2018 |
| <b>Age/Sex</b>      | 33/M              | <b>Client Code</b> | MOLQ1133CM         | <b>Specimen Type</b>     | Tissue     |
| <b>Patient ID</b>   | 011812060107      | <b>Ref. Doctor</b> |                    | <b>Collection Date</b>   | 06/12/2018 |
| <b>Specimen ID</b>  | MOLQ/B-1348/18    |                    |                    | <b>Report Date</b>       | 08/12/2018 |

## SURGICAL PATHOLOGY REPORT

### APPENDIX.

#### DIAGNOSIS

**ACUTE APPENDICITIS.**



#### SPECIMEN

Appendix.

#### GROSS

Received 6x1.5cm greyish white tissue piece.

#### Microscopy

1. Section examined shows lymphoid follicles with ulcerative mucosa.
2. Deeper tissue shows inflammatory cells.

**Note :** All biopsy specimen will be stored for 15 (fifteen) days, block and slides for 5 (five) years only from the time of receipt at the laboratory. No request, for any of the above, will be entertained after the due date.

#### Reference

- i) Rosai and Ackerman's Surgical Pathology.
- ii) Modern Surgical Pathology.

**Gulshan Yadav, MD**  
Consultant Pathologist