

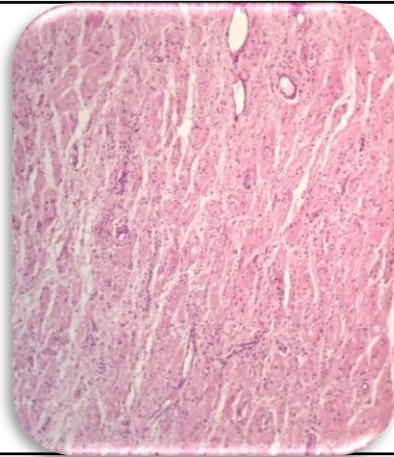
<b>Patient Name</b>	<b>Ms. ANURAG</b>	<b>Client Name</b>	Civil Hospital-P	<b>Specimen Received</b>	06/12/2018
<b>Age/Sex</b>	22 YRS/F		Gurgaon	<b>Specimen Type</b>	Tissue
<b>Patient ID</b>	011812060045	<b>Client Code</b>	MolQ1681P	<b>Collection Date</b>	06/12/2018
<b>Specimen ID</b>	MOLQ/B-1347/18	<b>Ref. Doctor</b>	Dr. SAURABH	<b>Report Date</b>	08/12/2018

## SURGICAL PATHOLOGY REPORT

### Testis

#### DIAGNOSIS

#### ATROPHIC TESTIS



#### SPECIMEN

Testis

#### GROSS

Received 3x2cm greyish white tissue piece.

#### Microscopy

1. Section examined shows fibrocollagenous capsule, blood vessels and seminiferous tubules with thick basement membrane. No immature and mature cells seen.

No malignant and no granuloma seen.

**Note :** All biopsy specimen will be stored for 15 (fifteen) days, block and slides for 5 (five) years only from the time of receipt at the laboratory. No request, for any of the above, will be entertained after the due date.

#### Reference

- i) Rosai and Ackerman's Surgical Pathology.
- ii) Modern Surgical Pathology.

**Gulshan Yadav, MD**  
Consultant Pathologist