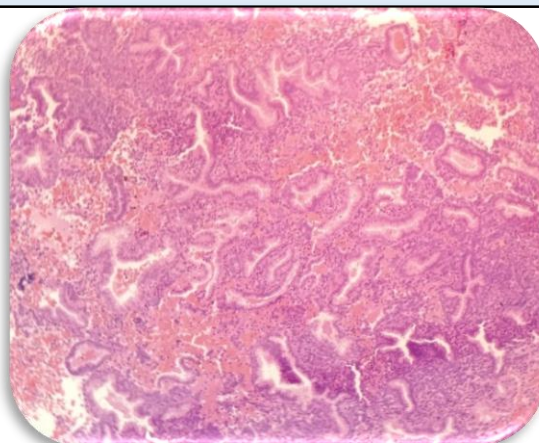


Patient Name	Mrs. POOJA W/O SONU	Client Name	Health Medicos,	Specimen Received	01/12/2018
Age/Sex	258Years/Female		Rohtak	Specimen Type	Tissue
Patient ID	011812010246	Client Code	MolQ1394CM	Collection Date	01/12/2018
Specimen ID	MOLQ/B-1324/18			Report Date	06/12/2018

SURGICAL PATHOLOGY REPORT

ENDOMETRIUM

DISORDERED PROLIFERATIVE PHASE



SPECIMEN

Endometrium

GROSS

Received multiple greyish white tissue piece.

Microscopy

1. Section examined shows small and tortuous endometrial glands having cuboidal to columnar lining epithelium with round to oval nucleus with vacuolization. Stroma shows mononuclear inflammatory cells.
2. No granuloma and no malignant cells seen.

Note : All biopsy specimen will be stored for 15 (fifteen) days, block and slides for 5 (five) years only from the time of receipt at the laboratory. No request for any of the above, will be entertained after the due date.

Reference

- i) Rosai and Ackerman's Surgical Pathology.
- ii) Modern Surgical Pathology.

Gulshan Yadav, MD
Consultant Pathologist