

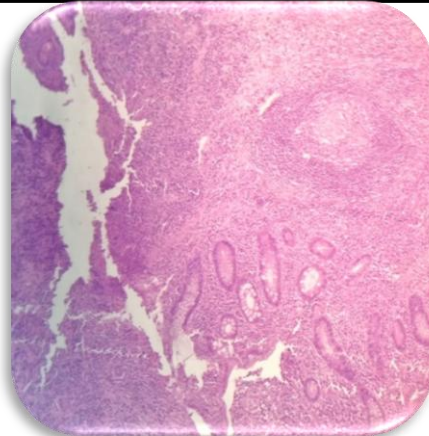
<b>Patient Name</b>	<b>Mrs. ANJU YADAV-20612</b>	<b>Client Name</b>	Pushpanjali Hospital	<b>Specimen Received</b>	24/11/2018
<b>Age/Sex</b>	30/F		(Rewari)	<b>Specimen Type</b>	Tissue
<b>Patient ID</b>	011811300172	<b>Client Code</b>	MolQ1789CM	<b>Collection Date</b>	24/11/2018
<b>Specimen ID</b>	MOLQ/B-1315/18	<b>Ref. Doctor</b>	DR KULDEEP	<b>Report Date</b>	04/12/2018

## SURGICAL PATHOLOGY REPORT

### APPENDIX CARCINOID TUMOR?

#### DIAGNOSIS

**ACUTE APPENDICITIS WITH GRANULOMATOUS REACTION.**



#### SPECIMEN

Appendix Carcinoid Tumor?

#### GROSS

Received 6x2 cm greyish white tissue piece. Cut section shows 1x2 cm solid mass.

#### Microscopy

- Section examined shows lymphoid follicle with ulcerative mucosa. Deeper tissue shows epithelioid cells, histiocytes with multinucleated giant cells and inflammatory cells.

**Note :** All biopsy specimen will be stored for 15 (fifteen) days, block and slides for 5 (five) years only from the time of receipt at the laboratory. No request, for any of the above, will be entertained after the due date.

#### Reference

- Rosai and Ackerman's Surgical Pathology.
- Modern Surgical Pathology.

**Gulshan Yadav, MD**  
Consultant Pathologist