

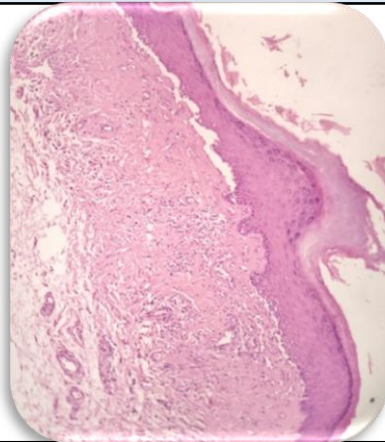
<b>Patient Name</b>	Mr. HARIOM-20443	<b>Client Name</b>	Pushpanjali Hospital	<b>Specimen Received</b>	27/11/2018
<b>Age/Sex</b>	35/M		(Rewari)	<b>Specimen Type</b>	Tissue
<b>Patient ID</b>	011811270233	<b>Client Code</b>	MolQ1789CM	<b>Collection Date</b>	27/11/2018
<b>Specimen ID</b>	MOLQ/B-1282-18	<b>Ref. Doctor</b>	DR S P YADAV	<b>Report Date</b>	30/11/2018

## SURGICAL PATHOLOGY REPORT

### Penile Skin (Leukoplakia)

#### DIAGNOSIS

**NON SPECIFIC INFLAMMATION**



#### SPECIMEN

Penile Skin (Leukoplakia)

#### GROSSING

Received 6x3 cm greyish white tissue piece with skin.

#### Microscopy

- Section examined shows hyperorthokeratotic squamous lining epithelium with round to oval nuclei overlying the connective tissue stroma.
- Stroma shows fibrocollagenous tissue and inflammatory cells (lymphocytes and plasma cells)

**Note :** All biopsy specimen will be stored for 15 (fifteen) days, block and slides for 5 (five) years only from the time of receipt at the laboratory. No request for any of the above will be entertained after the due date.

#### Reference

- Rosai and Ackerman's Surgical Pathology.
- Modern Surgical Pathology

**Gulshan Yadav, MD**  
Consultant Pathologist