

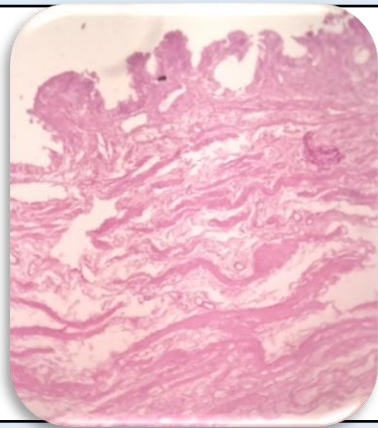
Patient Name	Mrs. CHANDER	Client Name	Pushpanjali Hospital, (Rewari)	Specimen Received	24/11/2018
Age/Sex	53/F	Client Code	MolQ1789CM	Specimen Type	Tissue
Patient ID	011811240183	Ref. Doc	DR KULDEEP	Collection Date	24/11/2018
Specimen ID	MOLQ/B-1284/18			Report Date	29/11/2018

SURGICAL PATHOLOGY REPORT

GALL BLADDER.

DIAGNOSIS

CHOLECYSTITIS AND CHOLELITHIASIS.



SPECIMEN

Gall Bladder.

GROSS

Received 6.2x1.3cm long gallbladder cut section shows stone.

Microscopy

- Section examined shows ulcerated lining epithelial and rokitansky aschoff sinus with inflammatory cells.

Note : All biopsy specimen will be stored for 15 (fifteen) days, block and slides for 5 (five) years only from the time of receipt at the laboratory. No request ,for any of the above will be entertained after the due date.

Reference

- Rosai and Ackerman's Surgical Pathology.
- Modern Surgical Pathology.

**Gulshan Yadav, MD
Consultant Pathologist**