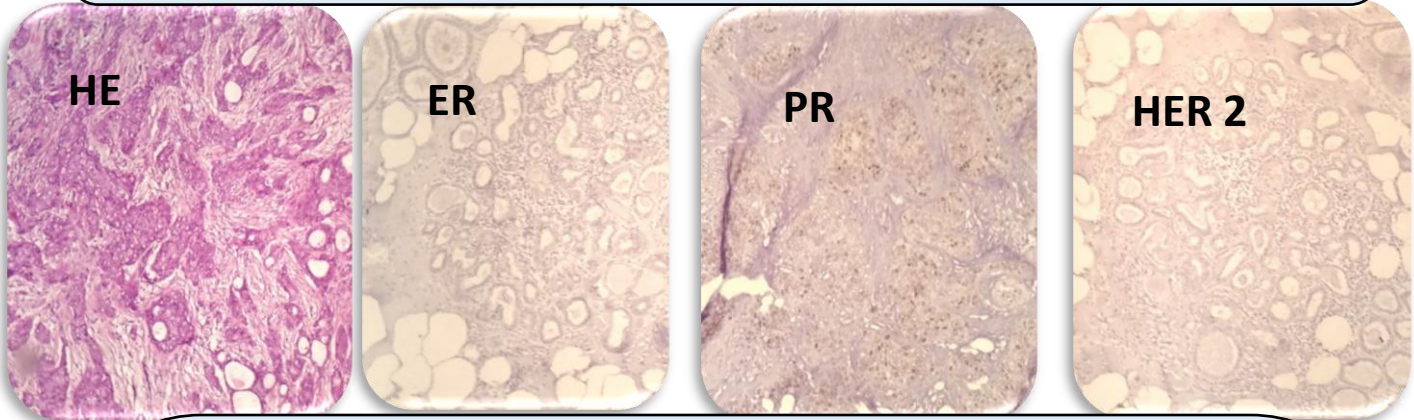


Patient Name	Mrs. VIDHYA DEVI	Client Name	Ubuntu Health Solutions	Specimen Received	22/11/2018
Age/Sex	45/F		Pvt. Ltd., Rhotak	Specimen Type	Tissue
Patient ID	011811220240	Client Code	MolQ1517CM	Collection Date	22/11/2018
Specimen ID	MOLQ/IHC-40/11/2018	Ref. Doctor	DR HARMEET SINGH	Report Date	26/11/2018

SURGICAL PATHOLOGY REPORT
INVASIVE DUCTAL CELL CARCINOMA

DIAGNOSIS

Estrogen Receptor α - Negative
Progesterone Receptor- Positive
Her-2/neu-Negative



Microscopic Findings:

Estrogen Receptor α (ER)

-% Cells immunoreactive – 00%

Intensity- 0

Internal control-Positive

Interpretation-Negative

Progesterone Receptor (PR)

% Cells immunoreactive – 40%

Intensity- +3

Internal control-Positive

Interpretation-Positive

Her-2/neu

% Cells immunoreactive – 00%

Intensity- 0

Internal control-Positive

Interpretation-Negative

Results Estrogen Receptor α - Negative

Progesterone Receptor-Positive

Her-2/neu-Negative

Reference

- i) Rosai and Ackerman's Surgical Pathology.
- ii) Modern Surgical Pathology.

SPECIMEN

ModifiedRadicalMastectomy(MRM)

Right Breast.

Gulshan Yadav, MD
Consultant Pathologist