

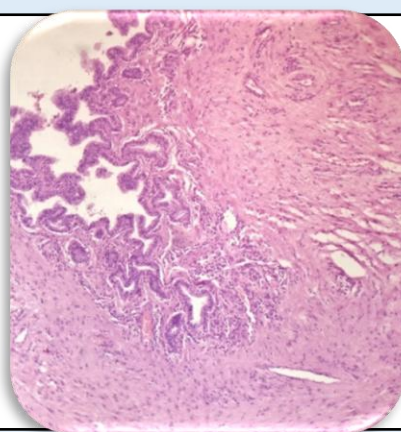
<b>Patient Name</b>	<b>Mrs. SEEMA</b>	<b>Client Name</b>	Civil Hospital-P	<b>Specimen Received</b>	20/11/2018
<b>Age/Sex</b>	25 Years/Female	<b>Client Code</b>	MolQ1681P	<b>Specimen Type</b>	Tissue
<b>Patient ID</b>	011811200328	<b>Ref. Doctor</b>	Mr. BALWINDER SINGH JI	<b>Collection Date</b>	20/11/2018
<b>Specimen ID</b>	MOLQ/B-1264/18			<b>Report Date</b>	22/10/2018

## SURGICAL PATHOLOGY REPORT

### Labial Cystic Lesion

#### DIAGNOSIS

**INFECTIVE CYSTIC LESION**



#### **SPECIMEN**

Labial Cystic Lesion

#### **GROSS**

Received 1x1cm greyish white tissue piece.

#### **Microscopy**

1. Section examined shows Squamous lining epithelial having round to oval nucleus.
2. Deeper tissue shows cyst line by cuboidal lining epithelial with round to oval nucleus with anisonucleosis.
3. Section also shows fibro collagenous.

**Gulshan Yadav, MD**  
Consultant Pathologist