

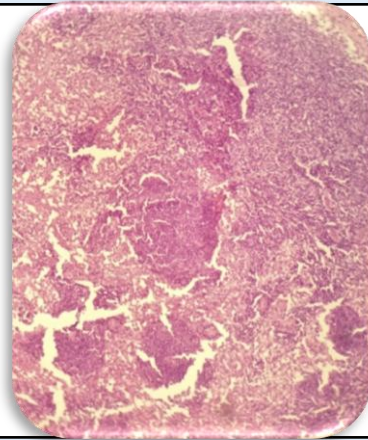
<b>Patient Name</b>	<b>Mr. TARA CHAND-19835</b>	<b>Client Name</b>	Pushpanjali Hospital (Rewari)	<b>Specimen Received</b>	19/11/2018
<b>Age/Sex</b>	70 Years/Male	<b>Client Code</b>	MolQ1789CM	<b>Specimen Type</b>	Tissue
<b>Patient ID</b>	011811190297	<b>Ref Doctor</b>	Dr. Kuldeep	<b>Collection Date</b>	19/11/2018
<b>Specimen ID</b>	MOLQ/B-1262/18			<b>Report Date</b>	21/11/2018

## SURGICAL PATHOLOGY REPORT

Mesenteric lymph node

### DIAGNOSIS

**REACTIVE LYMPHADENITIS**



#### SPECIMEN

Mesenteric lymph node

#### GROSS

Received 1x0.5 cm greyish white tissue piece bisected .

#### Microscopy

1. Section examined shows preserved architecture of lymph node with capsule and lymphoid follicles with centrocytes, lymphocyte and centroblast.
2. No malignant and no granuloma seen.

**Note :** All biopsy specimen will be stored for 15 (fifteen) days, block and slides for 5 (five) years only from the time of receipt at the laboratory. No request for any of the above will be entertained after the due date.

#### Reference

- i) Rosai and Ackerman's Surgical Pathology.
- ii) Modern Surgical Pathology.

**Gulshan Yadav, MD**  
**Consultant Pathologist**