

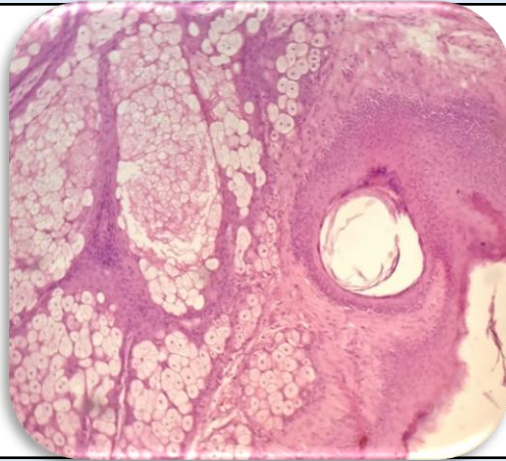
<b>Patient Name</b>	<b>Mrs. SUDESH</b>	<b>Client Name</b>	Chiranjeev Path Lab	<b>Specimen Received</b>	18/11/2018
<b>Age/Sex</b>	29/F	<b>Client Code</b>	MOLQ1019P	<b>Specimen Type</b>	Tissue
<b>Patient ID</b>	011811180020	<b>Ref. Doctor</b>		<b>Collection Date</b>	18/11/2018
<b>Specimen ID</b>	MOLQ/B-1259/18			<b>Report Date</b>	20/11/2018

## SURGICAL PATHOLOGY REPORT

Right ovarian lump

### DIAGNOSIS

**DERMOID CYST**



#### SPECIMEN

Right ovarian lump

#### GROSS

Received 6x5cm greyish white tissue piece. cut section shows cheesy material with hair.

#### Microscopy

Section examined shows squamous lining epithelial cell , keratin, blood vessel, adipose tissue and hair follicle.

No malignant and no granuloma seen.

**Note :** All biopsy specimen will be stored for 15 (fifteen)days, block and slides for 5(five) years only from the time of receipt at the laboratory. No request ,for any of the above, will be entertained after the due date.

#### Reference

- i) Rosai and Ackerman's Surgical Pathology.
- ii) Modern Surgical Pathology.

**Gulshan Yadav, MD**  
Consultant Pathologist