

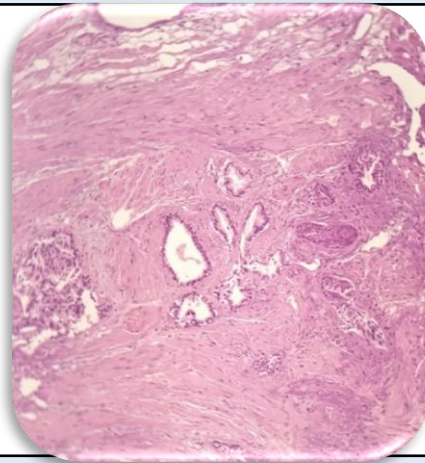
Patient Name	Mr. MOHINDER SINGH	Client Name	Pushpanjali Hospital (Rewari)	Specimen Received	16/11/2018
Age/Sex	71 YRS/M			Specimen Type	Tissue
Patient ID	011811160234	Client Code	MolQ1789CM	Collection Date	16/11/2018
Specimen ID	MOLQ/B-1255/18	Ref. Doctor	DR.KAMAL	Report Date	19/11/2018

SURGICAL PATHOLOGY REPORT

TURP

DIAGNOSIS

BENIGN PROSTATIC HYPERPLASIA.



SPECIMEN

TURP

GROSS

Received multiple greyish white tissue piece measuring 3x2.5cm in aggregate .

Microscopy

- Section examined shows bilayered prostatic glands with columnar lining epithelium and with small round to oval nucleus surrounded by large number of fibrocollagenous tissue and mononuclear inflammatory cell.

Note : All biopsy specimen will be stored for 15 (fifteen)days, block and slides for 5(five) years only from the time of receipt at the laboratory. No request ,for any of the above ,will be entertained after the due date.

Reference

- Rosai and Ackerman's Surgical Pathology.
- Modern Surgical Pathology.

Gulshan Yadav, MD
Consultant Pathologist