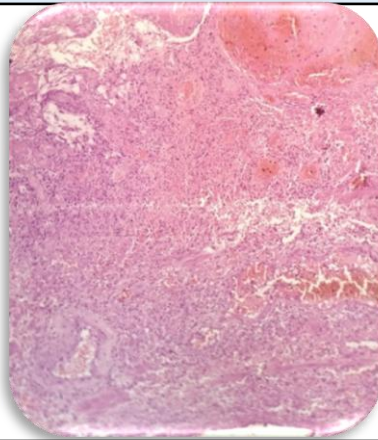


Patient Name	Mr. LALA RAM-9630	Client Name	Pushpanjali Hospital (Rewari)	Specimen Received	16/11/2018
Age/Sex	56/M	Client Code	MolQ1789CM	Specimen Type	Tissue
Patient ID	011811160231	Ref. Doctor	DR KULDEEP	Collection Date	16/11/2018
Specimen ID	MOLQ/B-1253/18			Report Date	19/11/2018

SURGICAL PATHOLOGY REPORT
HEMORRHOIDS

DIAGNOSIS

HEMORRHOIDS



SPECIMEN
Hemorrhoids

GROSS
Received two greyish white tissue piece
Size:2x3, 3x3 cm.

Microscopy

- Section examined shows submucosal glands, fibro collagenous tissue with blood vessels.No granuloma and no malignant cells seen.

Note : All biopsy specimen will be stored for 15 (fifteen)days, block and slides for 5(five) years only from the time of receipt at the laboratory. No request ,for any of the above ,will be entertained after the due date.

Reference

- Rosai and Ackerman's Surgical Pathology.
- Modern Surgical Pathology.

Gulshan Yadav, MD
Consultant Pathologist