

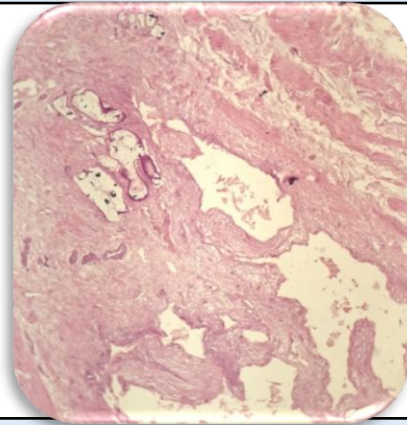
Patient Name	Mrs. CHANDANI	Client Name	Civil Hospital-P	Specimen Received	16/11/2018
Age/Sex	24/F			Specimen Type	Tissue
Patient ID	011811160196	Client Code	MolQ1681P	Collection Date	16/11/2018
Specimen ID	MOLQ/B-1251/18	Ref. Doctor	DR SAURABH DESWAL	Report Date	19/11/2018

SURGICAL PATHOLOGY REPORT

GALL BLADDER.

DIAGNOSIS

CHOLECYSTITIS AND CHOLELITHIASIS.



SPECIMEN

Gall Bladder.

GROSS

Received 6.5x3.8cm long gall bladder. Cut section shows stones

Microscopy

1. Section examined shows ulcerative mucosa and Rokitansky Aschoff sinuses with fibrocollagenous tissue and inflammatory cells.

Note : All biopsy specimen will be stored for 15 (fifteen) days, block and slides for 5 (five) years only from the time of receipt at the laboratory. No request, for any of the above, will be entertained after the due date.

Reference

- i) Rosai and Ackerman's Surgical Pathology.
- ii) Modern Surgical Pathology.



Gulshan Yadav, MD
Consultant Pathologist