

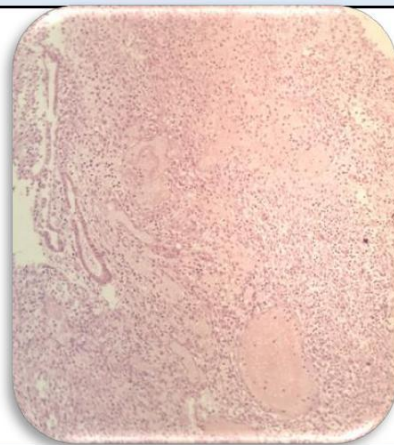
<b>Patient Name</b>	<b>Mrs. NEERU</b>	<b>Client Name</b>	Accurate Path (C), Agra	<b>Specimen Received</b>	13/11/2018
<b>Age/Sex</b>	40 Years/Female			<b>Specimen Type</b>	Tissue
<b>Patient ID</b>	011811130028	<b>Client Code</b>	MolQ1671CM	<b>Collection Date</b>	13/11/2018
<b>Specimen ID</b>	MOLQ/B-1234/18			<b>Report Date</b>	15/11/2018

## SURGICAL PATHOLOGY REPORT

### ENDOMETRIUM

#### IMPRESSION

**SIMPLE HYPERPLASIA WITHOUT ATYPIA AND HYPERPROGESTRONIC EFFECT.**



#### SPECIMEN

Endometrium

#### GROSS

Received multiple autolyzed tissue piece .

#### Microscopy

1. Section examined shows small and tortuous endometrial gland. Stroma shows mononuclear inflammatory cells.
2. No malignant and no granuloma seen.
3. Few gland are cystically dilated.

**Note :** All biopsy specimen will be stored for 15 (fifteen) days, block and slides for 5 (five) years only from the time of receipt at the laboratory. No request for any of the above, will be entertained after the due date.

#### Reference

- i) Rosai and Ackerman's Surgical Pathology.
- ii) Modern Surgical Pathology.

A handwritten signature in black ink, appearing to read 'Gulshan', written over a light blue rectangular background.

**Gulshan Yadav, MD**  
**Consultant Pathologist**