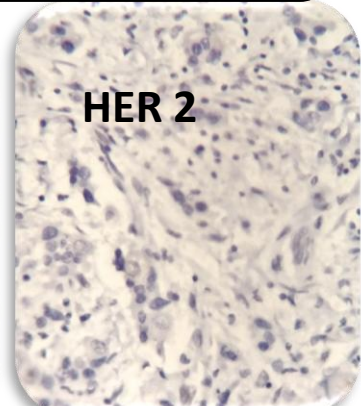
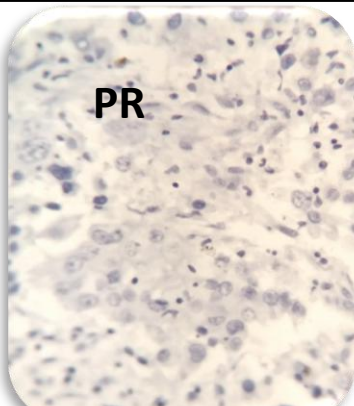
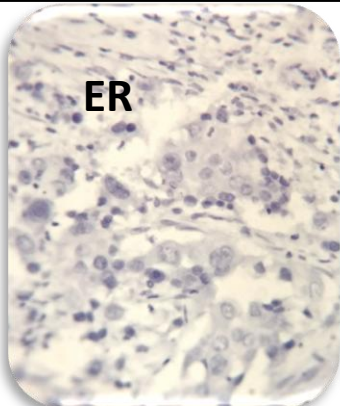
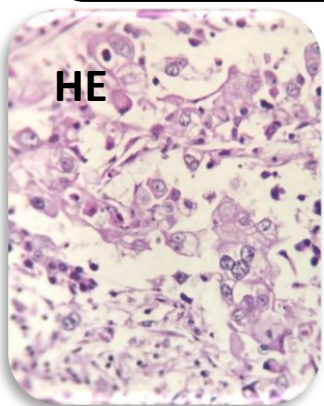


Patient Name	Mrs. LAXMI	Client Name	Nisha Path Lab	Specimen Received	15/11/2018
Age/Sex	50/F		Gurgaon	Specimen Type	Tissue
Patient ID	011810190131	Client Code	MolQ1782P	Collection Date	15/11/2018
Specimen ID	MOLQ/IHC-39/11/2018	Ref. Doctor		Report Date	19/11/2018

SURGICAL PATHOLOGY REPORT
DUCTAL CELL CARCINOMA, STAGE III

DIAGNOSIS

Estrogen Receptor α - Negative
Progesterone Receptor- Negative
Her-2/neu-Negative



Microscopic Findings:

Estrogen Receptor α (ER)
 -% Cells immunoreactive – 00%
 Intensity- 0
 Internal control-Positive
 Interpretation-Negative

Progesterone Receptor (PR)
 % Cells immunoreactive – 00%
 Intensity- 0
 Internal control-Positive
 Interpretation-Negative

Her-2/neu
 % Cells immunoreactive – 00%
 Intensity- 0
 Internal control-Positive
 Interpretation-Negative

Results Estrogen Receptor α - Negative
 Progesterone Receptor-Negative
 Her-2/neu-Negative

Reference

- i) Rosai and Ackerman's Surgical Pathology.
- ii) Modern Surgical Pathology.

SPECIMEN

ModifiedRadicalMastectomy(MRM)
 Right Breast.

Gulshan Yadav, MD
Consultant Pathologist