

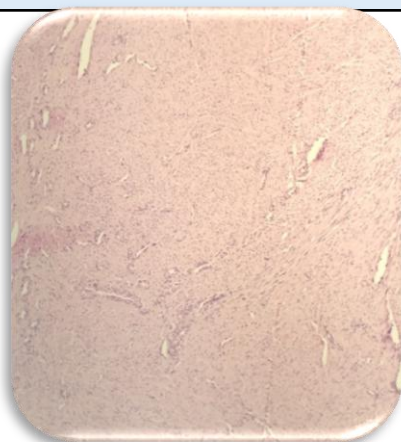
<b>Patient Name</b>	Mrs. ANJALI	<b>Client Name</b>	Uttam Diagnostics, Agra	<b>Specimen Received</b>	15/11/2018
<b>Age/Sex</b>	42/F	<b>Client Code</b>	MolQ1359CM	<b>Specimen Type</b>	Tissue
<b>Patient ID</b>	011811150001			<b>Collection Date</b>	15/11/2018
<b>Specimen ID</b>	MOLQ/B-1245/18			<b>Report Date</b>	16/11/2018

## SURGICAL PATHOLOGY REPORT

### UTERUS

#### DIAGNOSIS

**LEIOMYOMA**



#### SPECIMEN

Uterus

#### GROSS

Received 8x4.3cm uterus with cervix with bilateral adnexa cut section shows 2x2cm fibroid and ovary measuring 3x2 and 2x2cm .

#### Microscopy

Section examined shows

Endometrium with proliferative phase.

Myometrium with superficial adenomyosis.

Cervix with mononuclear inflammatory cells.

Fibroid with interlacing muscle bundle .


Ovary and tube unremarkable.

Other ovary and tube unremarkable

**Note :** All biopsy specimen will be stored for 15 (fifteen) days, block and slides for 5 (five) years only for

#### Reference

- i) Rosai and Ackerman's Surgical Pathology.
- ii) Modern Surgical Pathology.

  
**Gulshan Yadav, MD**  
**Consultant Pathologist**