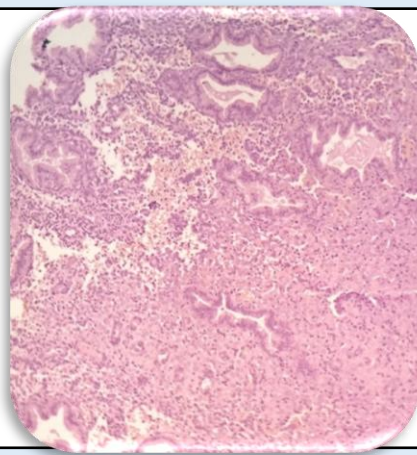


<b>Patient Name</b>	<b>Mr. KAMLESH-9332</b>	<b>Client Name</b>	Pushpanjali Hospital	<b>Specimen Received</b>	14/11/2018
<b>Age/Sex</b>	38 Years/male		(Rewari)	<b>Specimen Type</b>	Tissue
<b>Patient ID</b>	011811140265	<b>Client Code</b>	MolQ1789CM	<b>Collection Date</b>	14/11/2018
<b>Specimen ID</b>	MOLQ/B-1243/18	<b>Ref. Doc</b>	Dr. Kiran	<b>Report Date</b>	16/11/2018

## SURGICAL PATHOLOGY REPORT

### ENDOMETRIUM

#### DISORDERED PROLIFERATIVE PHASE



#### **SPECIMEN**

Endometrium

#### **GROSS**

Received multiple greyish white tissue piece.

#### **Microscopy**

1. Section examined shows small and tortuous endometrial gland having columnar to cuboidal lining epithelial with round to oval nucleus and vacuoles. Stroma shows mononuclear inflammatory cells
2. No malignant and no granuloma seen.

**Note :** All biopsy specimen will be stored for 15 (fifteen) days, block and slides for 5 (five) years only from the time of receipt at the laboratory. No request for any of the above, will be entertained after the due date.

#### **Reference**

- i) Rosai and Ackerman's Surgical Pathology.
- ii) Modern Surgical Pathology.

**Gulshan Yadav, MD**  
Consultant Pathologist