

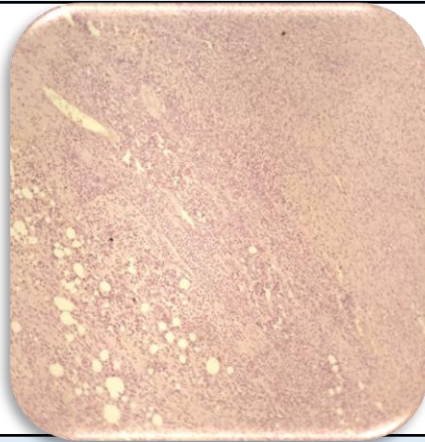
<b>Patient Name</b>	<b>Mr. PAWAN-9316</b>	<b>Client Name</b>	Pushpanjali Hospital (Rewari)	<b>Specimen Received</b>	<b>14/11/2018</b>
<b>Age/Sex</b>	37/M	<b>Client Code</b>	MolQ1789CM	<b>Specimen Type</b>	Tissue
<b>Patient ID</b>	011811140264	<b>Ref. Doctor</b>	DR KULDEEP	<b>Collection Date</b>	<b>14/11/2018</b>
<b>Specimen ID</b>	MOLQ/B-1240/18			<b>Report Date</b>	<b>16/11/2018</b>

## SURGICAL PATHOLOGY REPORT

### APPENDIX.

#### DIAGNOSIS

**ACUTE APPENDICITIS.**



#### **SPECIMEN**

Appendix.

#### **GROSS**

Received 8x1.1cm appendix. Cut section shows fecolith

#### **Microscopy**

1. Section examined shows lymphoid follicles with ulcerative mucosa.
2. Deeper tissue shows inflammatory cells.

**Note :** All biopsy specimen will be stored for 15 (fifteen) days, block and slides for 5 (five) years only from the time of receipt at the laboratory. No request, for any of the above, will be entertained after the due date.

#### **Reference**

- i) Rosai and Ackerman's Surgical Pathology.
- ii) Modern Surgical Pathology.

**Gulshan Yadav, MD  
Consultant Pathologist**