

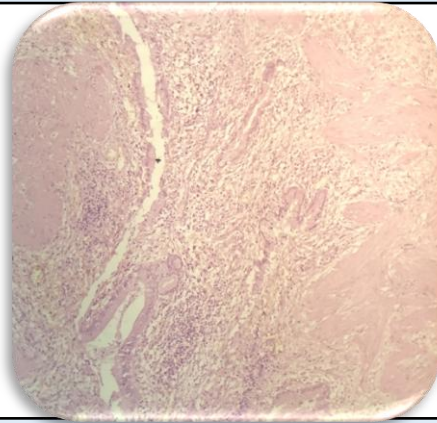
Patient Name	Mrs. BIRMATI-18372	Client Name	Pushpanjali Hospital (Rewari)	Specimen Received	14/11/2018
Age/Sex	57/F	Client Code	MolQ1789CM	Specimen Type	Tissue
Patient ID	011811140263			Collection Date	14/11/2018
Specimen ID	MOLQ/B-1241/18			Report Date	16/11/2018

SURGICAL PATHOLOGY REPORT

GALL BLADDER.

DIAGNOSIS

CHOLECYSTITIS AND CHOLELITHIASIS.



SPECIMEN

Gall Bladder.

GROSS

Received 6.2x2.8cm long gallbladder cut section shows stone.

Microscopy

1. Section examined shows ulcerative mucosa and rokitansky aschoff sinus with fibrocollagenous tissue and inflammatory cells.

Note : All biopsy specimen will be stored for 15 (fifteen)days, block and slides for 5(five) years only from the time of receipt at the laboratory. No request ,for any of the above ,will be entertained after the due date.

Reference

- i) Rosai and Ackerman's Surgical Pathology.
- ii) Modern Surgical Pathology.

**Gulshan Yadav, MD
Consultant Pathologist**