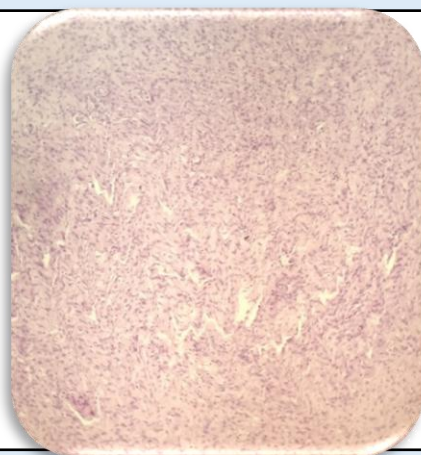


<b>Patient Name</b>	<b>Mrs. NEETU</b>	<b>Client Name</b>	Arban Hospital	<b>Specimen Received</b>	13/11/2018
<b>Age/Sex</b>	20 Years/Female	<b>Client Code</b>	MolQ1684P	<b>Specimen Type</b>	Tissue
<b>Patient ID</b>	011811130258			<b>Collection Date</b>	13/11/2018
<b>Specimen ID</b>	MOLQ/B-1238/18			<b>Report Date</b>	15/11/2018

## SURGICAL PATHOLOGY REPORT

### Endometriotic Cyst?

#### ENDOMETRIOTIC CYST



#### SPECIMEN

Endometriotic Cyst?

#### GROSS

Received 4 tissue piece measuring 6x6cm, 8x4cm, 4x3cm, and 3x3cm .

#### Microscopy

1. Section examined shows stromal cells with glands having small round nucleus and blood vessel.
2. Tube unremarkable

**Note :** All biopsy specimen will be stored for 15 (fifteen) days, block and slides for 5 (five) years only from the time of receipt at the laboratory. No request for any of the above, will be entertained after the due date.

#### Reference

- i) Rosai and Ackerman's Surgical Pathology.
- ii) Modern Surgical Pathology.

**Gulshan Yadav, MD**  
**Consultant Pathologist**