

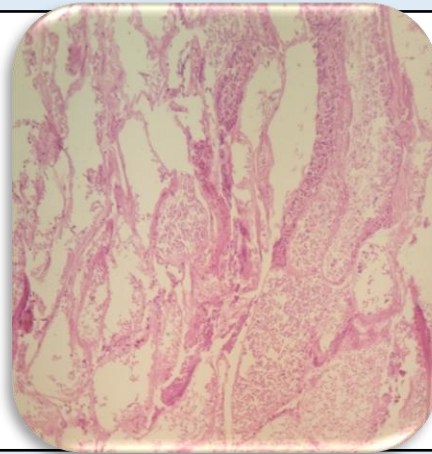
Patient Name	Mr. RAM SEVAK	Client Name	Asian Diagnostic Centre,	Specimen Received	10/11/2018
Age/Sex	52/M		New Delhi	Specimen Type	Tissue
Patient ID	011811100197	Client Code	MolQ1300CW	Collection Date	10/11/2018
Specimen ID	MOLQ/B-1222-18	Ref. Doctor		Report Date	16/11/2018

SURGICAL PATHOLOGY REPORT

Testis

DIAGNOSIS

ATROPHIC TESTIS WITH INFECTIVE CHANGES



SPECIMEN

Testis

GROSSING

Received multiple greyish white tissue piece.

Microscopy

1. Section examined shows seminiferous tubules with degenerated changes with thick basement membrane and supporting cell with inflammatory cells. No granuloma and malignant cells seen.

Note : All biopsy specimen will be stored for 15 (fifteen)days, block and slides for 5(five) years only from the time of receipt at the laboratory. No request ,for any of the above ,will be entertained after the due date.

Reference

- i) Rosai and Ackerman's Surgical Pathology.
- ii) Modern Surgical Pathology

Gulshan Yadav, MD
Consultant Pathologist