

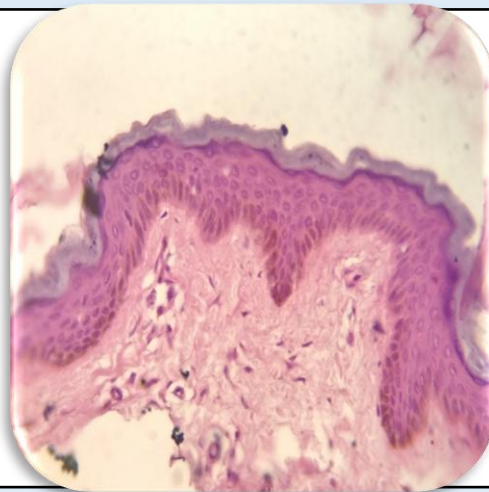
Patient Name	Mr. DHURI SINGH	Client Name	Pushpanjali Hospital (Rewari)	Specimen Received	12/11/2018
Age/Sex	60/M	Client Code	MolQ1789CM	Specimen Type	Tissue
Patient ID	011811120220	Ref. Doctor	DR.MUKESH	Collection Date	12/11/2018
Specimen ID	MOLQ/B-1233-18			Report Date	14/11/2018

SURGICAL PATHOLOGY REPORT

WART RIGHT THIGH

DIAGNOSIS

CORN



SPECIMEN

Wart Right Thigh

GROSSING

Received 2x11 cm greyish white tissue piece.

Microscopy

- Section examined shows squamous epithelial lining with round to oval nucleus, melanin pigmentation and keratosis and parakeratosis. Deeper tissue shows fibrocollagenous tissue, blood vessels and inflammatory cells.
- No granuloma and no malignant cells seen.

Note : All biopsy specimen will be stored for 15 (fifteen) days, block and slides for 5 (five) years only from the time of receipt at the laboratory. No request, for any of the above, will be entertained after the due date.

Reference

- Rosai and Ackerman's Surgical Pathology.
- Modern Surgical Pathology

Gulshan Yadav, MD
Consultant Pathologist