

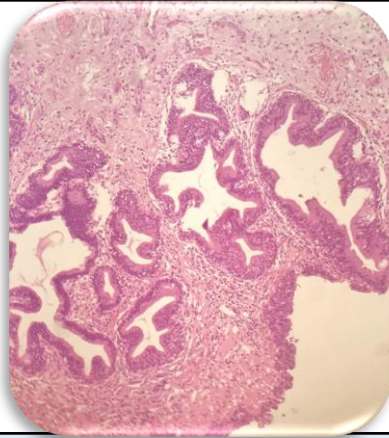
Patient Name	Mr. SATYBRATA BEHRA	Client Name	Care Diagnostics Centre	Specimen Received	10/11/2018
Age/Sex	33 Years/Male	Client Code	MolQ1522P	Specimen Type	Tissue
Patient ID	011811100245			Collection Date	10/11/2018
Specimen ID	MOLQ/B-1224/18			Report Date	14/10/2018

SURGICAL PATHOLOGY REPORT

Urinary Bladder

DIAGNOSIS

CYSTITIS GLANDULARIS-MUCINOUS TYPE



SPECIMEN

Urinary Bladder

GROSS

Received multiple greyish white tissue piece.

Microscopy

1. Section examined shows transitional epithelial lining of the bladder (Urothelium) with lamina propria. Epithelium showing metaplastic changes of mucous secreting glands without atypia surrounded by dense and focal chronic inflammatory cells.
2. No granuloma and no malignant cells seen.

Note : All biopsy specimen will be stored for 15 (fifteen) days, block and slides for 5 (five) years only from the time of receipt at the laboratory. No request ,for any of the above ,will be entertained after the due date.

Reference

- i) Rosai and Ackerman's Surgical Pathology.
- ii) Modern Surgical Pathology.

Gulshan Yadav, MD
Consultant Pathologist