

Patient Name	Mrs. SAROJ	Client Name	Arban Hospital	Specimen Received	05/11/2018
Age/Sex	52/F	Client Code	MolQ1684P	Specimen Type	Tissue
Patient ID	011811050155	Ref. Doctor		Collection Date	05/11/2018
Specimen ID	MOLQ/B-1210-18			Report Date	12/11/2018

SURGICAL PATHOLOGY REPORT

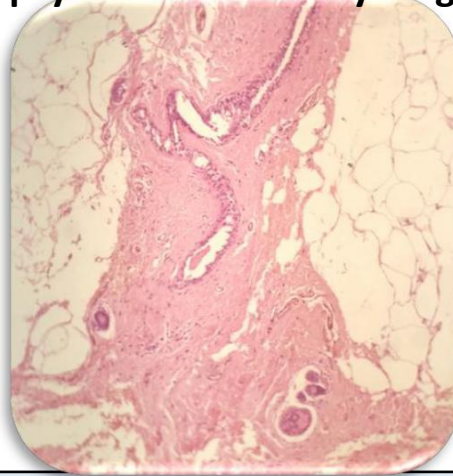
RIGHT BREAST

DIAGNOSIS

IMPRESSION

KINDLY, CO-RELATE CLINICALLY AND RADIOLOGICALLY.

Advised: Deeper Biopsy for confirmatory diagnosis.



SPECIMEN

Right Breast

GROSSING

Received multiple greyish white tissue piece.

Microscopy

1. Section examined shows mature adipose cells and fibrocollagenous tissue.
2. Section also shows ducts lined by cuboidal lining epithelium with round to oval nucleus and mild anisonucleosis.

Note : All biopsy specimen will be stored for 15 (fifteen) days, block and slides for 5 (five) years only from the time of receipt at the laboratory. No request, for any of the above, will be entertained after the due date.

Reference

- i) Rosai and Ackerman's Surgical Pathology.
- ii) Modern Surgical Pathology

Gulshan Yadav, MD
Consultant Pathologist