

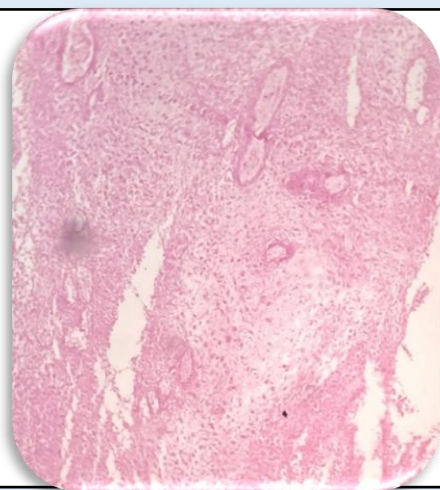
Patient Name	Mrs. ANJU GOYAL	Client Name	Lifeaid Wellness Centre,	Specimen Received	02/11/2018
Age/Sex	50/F		Gurgaon	Specimen Type	Tissue
Patient ID	011811020033	Client Code	MolQ1476CM	Collection Date	02/11/2018
Specimen ID	MOLQ/B-1203-18	Ref. Doctor		Report Date	06/11/2018

SURGICAL PATHOLOGY REPORT

FALLOPIAN TUBE

DIAGNOSIS

SUSPICIOUS OF HYPERPROGESTRONIC EFFECT



SPECIMEN

Fallopian tube

GROSSING

Received 1x0.5 cm two greyish white tissue piece in single container.

Microscopy

- Section examined from autolyzed tissue shows stromal cells, decidual cells and autolyzed gland.

Note : All biopsy specimen will be stored for 15 (fifteen)days, block and slides for 5(five) years only from the time of receipt at the laboratory. No request ,for any of the above ,will be entertained after the due date.

Reference

- Rosai and Ackerman's Surgical Pathology.
- Modern Surgical Pathology

Gulshan Yadav, MD
Consultant Pathologist