

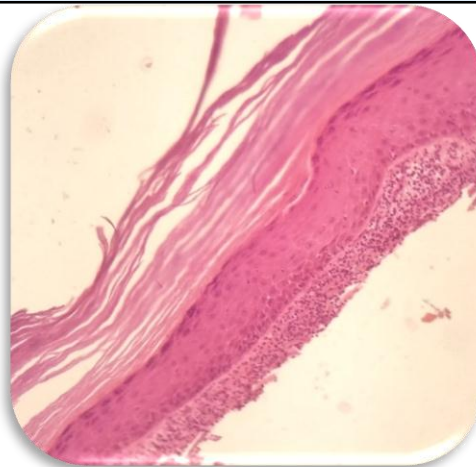
<b>Patient Name</b>	Mr. ISHWAR SINGH	<b>Client Name</b>	Lifeaid Wellness Centre	<b>Specimen Received</b>	31/10/2018
<b>Age/Sex</b>	58/M		Gurgaon	<b>Specimen Type</b>	Tissue
<b>Patient ID</b>	011810310197	<b>Client Code</b>	MolQ1476CM	<b>Collection Date</b>	31/10/2018
<b>Specimen ID</b>	MOLQ/B-1197/18	<b>Ref. Doctor</b>	DR AMANDEEP SAHAN	<b>Report Date</b>	02/10/2018

## SURGICAL PATHOLOGY REPORT

### SEBACEOUS CYST

#### DIAGNOSIS

#### SEBACEOUS CYST



#### SPECIMEN

Sebaceous cyst

#### GROSS

Received 3X2cm greyish white tissue piece.

#### Microscopy

- Section examined shows squamous lining epithelial cell with round nucleus and keratin. Deeper tissue shows fibro collagenous cells and blood vessels.

**Note :** All biopsy specimen will be stored for 15 (fifteen) days, block and slides for 5 (five) years only from the time of receipt at the laboratory. No request ,for any of the above ,will be entertained after the due date.

#### Reference

- Rosai and Ackerman's Surgical Pathology.
- Modern Surgical Pathology.

**Gulshan Yadav, MD**  
Consultant Pathologist