

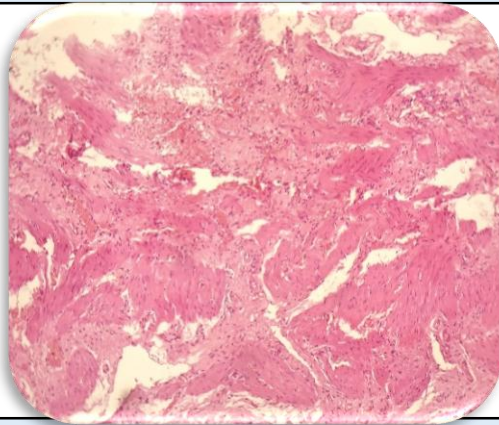
<b>Patient Name</b>	Mrs. REKHA	<b>Client Name</b>	Asian Diagnostic Centre,	<b>Specimen Received</b>	26/10/2018
<b>Age/Sex</b>	30/F		New Delhi	<b>Specimen Type</b>	Tissue
<b>Patient ID</b>	011810260223	<b>Client Code</b>	MolQ1300CW	<b>Collection Date</b>	26/10/2018
<b>Specimen ID</b>	MOLQ/B-1172-18	<b>Ref. Doctor</b>		<b>Report Date</b>	29/10/2018

## SURGICAL PATHOLOGY REPORT

### GALL BLADDER.

#### DIAGNOSIS

**CHOLECYSTITIS AND CHOLELITHIASIS.**



#### **SPECIMEN**

Gall Bladder.

#### **GROSS**

Received 6.2x3.2cm long gallbladder cut section shows tiny stone.

#### **Microscopy**

1. Section examined shows ulcerative mucosa and rokitansky aschoff sinus with fibrocollagenous tissue.

**Note :** All biopsy specimen will be stored for 15 (fifteen)days, block and slides for 5(five) years only from the time of receipt at the laboratory. No request ,for any of the above ,will be entertained after the due date.

#### **Reference**

- i) Rosai and Ackerman's Surgical Pathology.
- ii) Modern Surgical Pathology.

**Gulshan Yadav, MD  
Consultant Pathologist**