

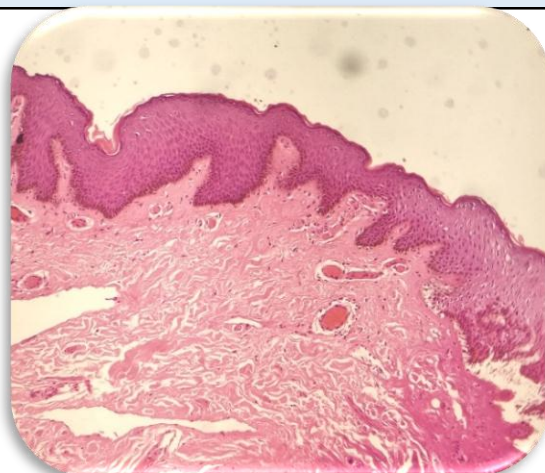
<b>Patient Name</b>	Mr. MAHESH	<b>Client Name</b>	Vedic Hospital	<b>Specimen Received</b>	25/10/2018
<b>Age/Sex</b>	30/M		Gurgaon	<b>Specimen Type</b>	Tissue
<b>Patient ID</b>	011810250028	<b>Client Code</b>	MolQ1492CM	<b>Collection Date</b>	25/10/2018
<b>Specimen ID</b>	MOLQ/B-1167/18	<b>Ref. Doctor</b>		<b>Report Date</b>	30/10/2018

## SURGICAL PATHOLOGY REPORT

### Soft Tissue Tumour Scrotum

#### DIAGNOSIS

#### SEBACEOUS CYST



#### SPECIMEN

Soft tissue tumour scrotum

#### GROSS

Received 6x2 cm greyish white tissue piece cut section shows cheese material.

#### Microscopy

1. Section examined shows Squamous lining epithelial dermal tissue with keratin flakes.
2. No malignant and no granuloma seen.

**Note :** All biopsy specimen will be stored for 15 (fifteen) days, block and slides for 5 (five) years only from the time of receipt at the laboratory. No request ,for any of the above ,will be entertained after the due date.

#### Reference

- i) Rosai and Ackerman's Surgical Pathology.
- ii) Modern Surgical Pathology.

**Gulshan Yadav, MD**  
Consultant Pathologist