

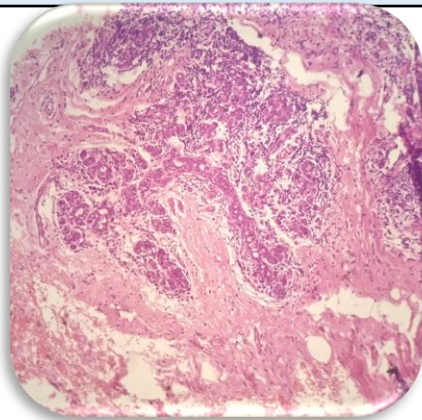
Patient Name	Mrs. AMARLATA-15350	Client Name	Pushpanjali Hospital	Specimen Received	23/10/2018
Age/Sex	29 Years/Female		Rewari	Specimen Type	Tissue
Patient ID	011810220302	Client Code	MolQ1789CM	Collection Date	23/10/2018
Specimen ID	MOLQ/B-1159/18	Ref. Doctor		Report Date	25/10/2018

SURGICAL PATHOLOGY REPORT

Left axillary swelling

DIAGNOSIS

BENIGN MESENCHYMAL LESION WITH REACTIVE LYMPHADENITIS



SPECIMEN

Gall Bladder.

GROSS

Received 3x2 cm greyish white tissue piece cut section shows necrotic cheese material .

Microscopy

1. Section examined shows mature adipose cell blood vessels glands with mononuclear inflammatory cell and lymphoid follicles .
2. No malignant and no granuloma seen

Note : All biopsy specimen will be stored for 15 (fifteen)days, block and slides for 5(five) years only from the time of receipt at the laboratory. No request ,for any of the above ,will be entertained after the due date.

Reference

- i) Rosai and Ackerman's Surgical Pathology.
- ii) Modern Surgical Pathology.

Gulshan Yadav, MD
Consultant Pathologist