

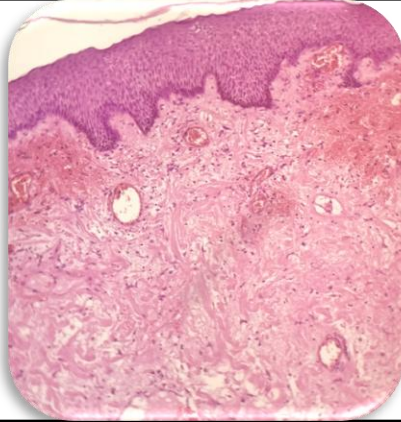
Patient Name	Mrs. SHEETAL	Client Name	Cygnus SuperSpeciality	Specimen Received	20/10/2018
Age/Sex	35/F		Hospital, Rewari	Specimen Type	Tissue
Patient ID	011810200304	Client Code	MolQ1687CM	Collection Date	22/10/2018
Specimen ID	MOLQ/B-1154-18	Ref. Doctor		Report Date	24/10/2018

SURGICAL PATHOLOGY REPORT

NEVI

DIAGNOSIS

NEVI



SPECIMEN

NEVI

GROSSING

Received 1x1cm greyish white tissue piece.

Microscopy

1. Section examined shows squamous lining epithelial with mild hyperplasia having round to oval nucleus.
2. Basal layer shows melanin pigment.
3. Deeper tissue shows blood vessels and fibrocollagenous tissue.
4. No malignant and no granuloma seen.

Note : All biopsy specimen will be stored for 15 (fifteen)days, block and slides for 5(five) years only from the time of receipt at the laboratory. No request ,for any of the above ,will be entertained after the due date.

Reference

- i) Rosai and Ackerman's Surgical Pathology.
- ii) Modern Surgical Pathology

Gulshan Yadav, MD
Consultant Pathologist