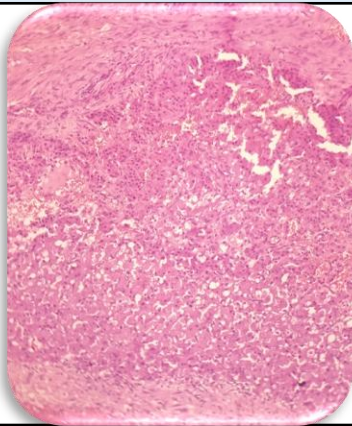


Patient Name	Mrs. NEETU SINGH	Client Name	Lifeaid Wellness Centre	Specimen Received	18/10/2018
Age/Sex	32/F		Gurgaon	Specimen Type	Tissue
Patient ID	011810180056	Client Code	MolQ1476CM	Collection Date	18/10/2018
Specimen ID	MOLQ/B-1145-18	Ref. Doctor		Report Date	24/10/2018

SURGICAL PATHOLOGY REPORT
RIGHT SALPINGO OOPHORECTOMY WITH MASS

DIAGNOSIS

OVARIAN ECTOPIC PREGNANCY



SPECIMEN

Right salpingo oophorectomy with Mass

GROSSING

Container 1) Received two bits of tubular tissue piece.
 Container 2) Received 2.3 x 1.3 cm greyish white tissue piece.

Microscopy

- Section from ovary shows blood clot with trophoblastic cells and decidual cells. Tubes are unremarkable.

Note : All biopsy specimen will be stored for 15 (fifteen)days, block and slides for 5(five) years only from the time of receipt at the laboratory. No request ,for any of the above ,will be entertained after the due date.

Reference

- Rosai and Ackerman's Surgical Pathology.
- Modern Surgical Pathology

Gulshan Yadav, MD
Consultant Pathologist