

Patient Name	Mrs. MANISHA	Client Name	Civil Hospital-P	Specimen Received	20/10/2018
Age/Sex	37/F	Client Code	MolQ1681P	Specimen Type	Tissue
Patient ID	011810200278	Ref. Doctor	DR.SAURABH DESWAL	Collection Date	20/10/2018
Specimen ID	MOLQ/B-1155/18			Report Date	23/10/2018

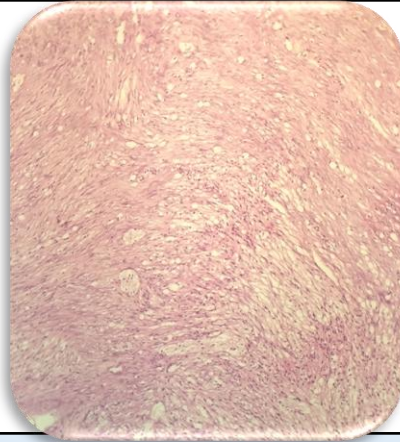
SURGICAL PATHOLOGY REPORT

APPENDIX.

DIAGNOSIS

ACUTE APPENDICITIS.

Kindly correlate radiologically and clinically.



SPECIMEN

Appendix.

GROSS

Received autolyzed two tissue piece measuring 1x1cm E/A

Microscopy

1. Section examined shows no lining epithelium with fibrocollagenous tissue, adipose cells and inflammatory cells.

Note : All biopsy specimen will be stored for 15 (fifteen)days, block and slides for 5(five) years only from the time of receipt at the laboratory. No request ,for any of the above ,will be entertained after the due date.

Reference

- i) Rosai and Ackerman's Surgical Pathology.
- ii) Modern Surgical Pathology.

A handwritten signature in black ink, appearing to read 'Gulshan', written over a light blue rectangular background.

**Gulshan Yadav, MD
Consultant Pathologist**