

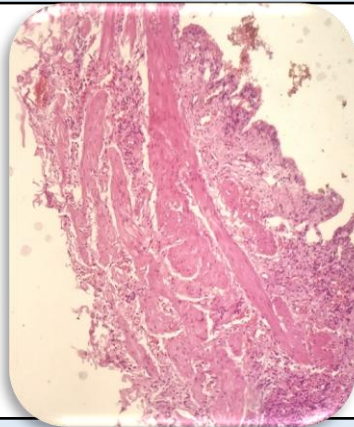
Patient Name	Mrs. SHAKUNTALA	Client Name	Pushpanjali Hospital (Rewari)	Specimen Received	19/10/2018
Age/Sex	46/F	Client Code	MolQ1789CM	Specimen Type	Tissue
Patient ID	011810190205	Ref. Doctor	DR KULDEEP	Collection Date	19/10/2018
Specimen ID	MOLQ/B-1151-18			Report Date	22/10/2018

SURGICAL PATHOLOGY REPORT

GALL BLADDER.

DIAGNOSIS

CHOLECYSTITIS AND CHOLELITHIASIS.



SPECIMEN

Gall Bladder.

GROSS

Received 6.5x3.2 cm long gall bladder. Cut section shows multiple stone.

Microscopy

1. Section examined shows ulcerative mucosa and Rokitansky-Aschoff sinuses with fibrocollagenous tissue.

Note : All biopsy specimen will be stored for 15 (fifteen) days, block and slides for 5 (five) years only from the time of receipt at the laboratory. No request, for any of the above, will be entertained after the due date.

Reference

- i) Rosai and Ackerman's Surgical Pathology.
- ii) Modern Surgical Pathology.

Gulshan Yadav, MD
Consultant Pathologist