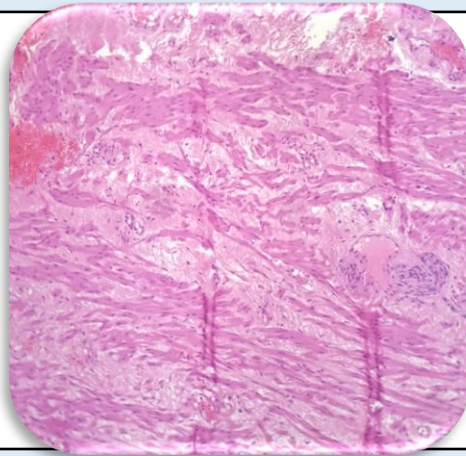


Patient Name	Mr. HARI SINGH	Client Name	Pushpanjali Hospital (Rewari)	Specimen Received	19/10/2018
Age/Sex	32/M	Client Code	MolQ1789CM	Specimen Type	Tissue
Patient ID	011810190196	Ref. Doctor	DR KULDEEP	Collection Date	19/10/2018
Specimen ID	MOLQ/B-1150-18			Report Date	23/10/2018

SURGICAL PATHOLOGY REPORT
HEMORRHOIDS

DIAGNOSIS

HEMORRHOIDS



SPECIMEN
Hemorrhoids

GROSS
Received multiple greyish white tissue piece.

Microscopy

1. Section examined shows epithelial lining, submucosal glands, fibro collagenous tissue with blood vessels.
2. No granuloma and no malignant cells seen.

Note : All biopsy specimen will be stored for 15 (fifteen) days, block and slides for 5 (five) years only from the time of receipt at the laboratory. No request for any of the above ,will be entertained after the due date.

Reference

- i) Rosai and Ackerman's Surgical Pathology.
- ii) Modern Surgical Pathology.

Gulshan Yadav, MD
Consultant Pathologist