

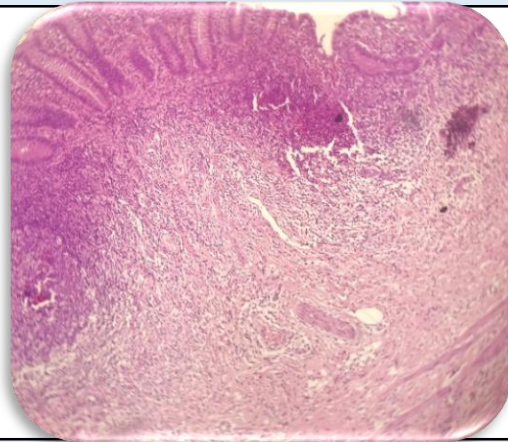
<b>Patient Name</b>	Master. YASH	<b>Client Name</b>	Pushpanjali Hospital (Rewari)	<b>Specimen Received</b>	18/10/2018
<b>Age/Sex</b>	11/M	<b>Client Code</b>	MolQ1789CM	<b>Specimen Type</b>	Tissue
<b>Patient ID</b>	011810180254	<b>Ref. Doctor</b>	DR KULDEEP	<b>Collection Date</b>	18/10/2018
<b>Specimen ID</b>	MOLQ/B-1143/18			<b>Report Date</b>	22/10/2018

## SURGICAL PATHOLOGY REPORT

### APPENDIX.

#### DIAGNOSIS

**ACUTE APPENDICITIS.**



#### SPECIMEN

Appendix.

#### GROSS

Received 4x2 cm long appendix cut section shows fecolith .

#### Microscopy

1. Section examined shows lymphoid follicles with ulcerative mucosa.
2. Deeper tissue shows inflammatory cells.

**Note :** All biopsy specimen will be stored for 15 (fifteen) days, block and slides for 5 (five) years only from the time of receipt at the laboratory. No request ,for any of the above ,will be entertained after the due date.

#### Reference

- i) Rosai and Ackerman's Surgical Pathology.
- ii) Modern Surgical Pathology.

**Gulshan Yadav, MD**  
Consultant Pathologist