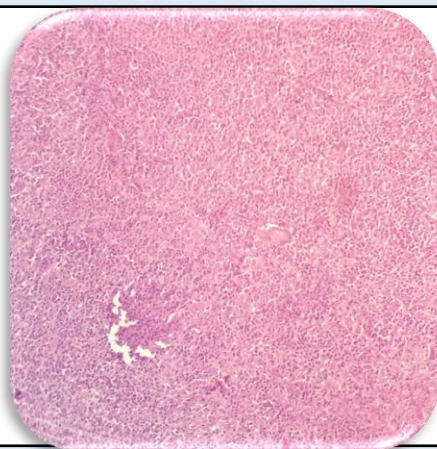


Patient Name	Mr. DHASRAT SINGH	Client Name	Kamal Hospital and	Specimen Received	17/10/2018
Age/Sex	65 Years/Male		Maternity Center	Specimen Type	Tissue
Patient ID	011810170180			Collection Date	17/10/2018
Specimen ID	MOLQ/B-1138/18	Client Code	MolQ1329CM	Report Date	22/10/2018

SURGICAL PATHOLOGY REPORT

Axillary lymph node

GRANULOMATOUS REACTION (TUBERCULAR PATHOLOGY)



SPECIMEN

Axillary lymph node

GROSS

Received 3.5x 2.8 cm greyish white tissue piece cut section shows solid mass .

Microscopy

1. Section examined shows lymphoid follicles with intact capsule .
2. Section shows epithelioid cell granuloma with caseous necrosis.

Note : All biopsy specimen will be stored for 15 (fifteen) days, block and slides for 5 (five) years only from the time of receipt at the laboratory. No request for any of the above, will be entertained after the due date.

Reference

- i) Rosai and Ackerman's Surgical Pathology.
- ii) Modern Surgical Pathology.

Gulshan Yadav, MD
Consultant Pathologist