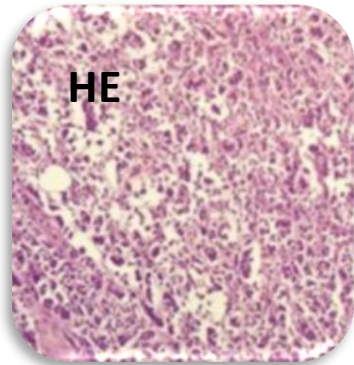


Patient Name	Mrs. MITHLESH	Client Name	C/O LEELAWATI HOSPITAL	Specimen Received	03/10/2018
Age/Sex	50/F		AGRA	Specimen Type	Tissue
Patient ID	011810030022	Client Code	Walk-in	Collection Date	03/10/2018
Specimen ID	MOLQ/IHC-28/10/2018	Ref. Doctor		Report Date	15/10/2018

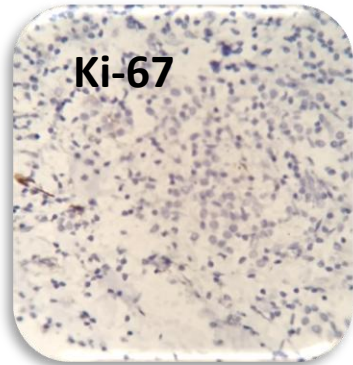
SURGICAL PATHOLOGY REPORT
DUCTAL CELL CARCINOMA, STAGE III

DIAGNOSIS

Ki-67 Receptor- Negative



HE



Ki-67

Microscopic Findings:

Ki-67 Receptor
 % Cells immunoreactive – 00%
 Intensity- 00
 Internal control-Positive
 Interpretation-Negative

SPECIMEN

ModifiedRadicalMastectomy(MRM)
 LeftBreast.

Results

Ki-67 Receptor- Negative

Reference

- i) Rosai and Ackerman's Surgical Pathology.
- ii) Modern Surgical Pathology.

Gulshan Yadav, MD
Consultant Pathologist