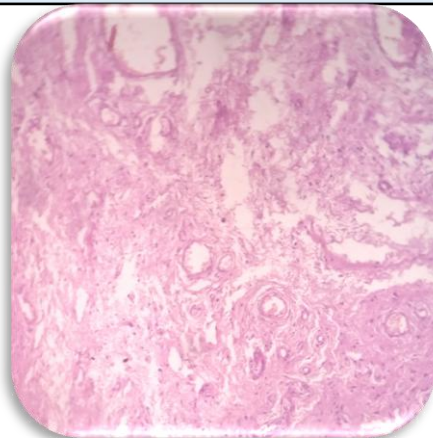


Patient Name	Mrs. KAILASH DEVI	Client Name	Pushpanjali Hospital (Rewari)	Specimen Received	23/09/2018
Age/Sex	50/F	Client Code	M olQ1492CM	Specimen Type	Tissue
Patient ID	011809230211	Ref. Doctor	DR.KULDEEP	Collection Date	23/09/2018
Specimen ID	MOLQ/B-1026-18			Report Date	26/09/2018

SURGICAL PATHOLOGY REPORT
HEMORRHOIDS

DIAGNOSIS

HEMORRHOIDS



SPECIMEN
Hemorrhoids

GROSS
Received 4x1cm greyish white tissue piece.

Microscopy

- Section examined shows submucosal glands, fibro collagenous tissue with blood vessels.No granuloma and no malignant cells seen.

Note : All biopsy specimen will be stored for 15 (fifteen)days, block and slides for 5(five) years only from the time of receipt at the laboratory. No request ,for any of the above ,will be entertained after the due date.

Reference

- Rosai and Ackerman's Surgical Pathology.
- Modern Surgical Pathology.

Gulshan Yadav, MD
Consultant Pathologist