

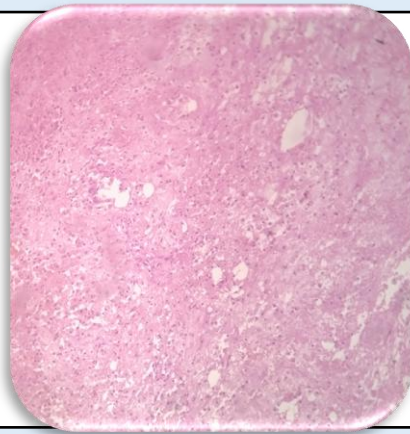
<b>Patient Name</b>	Mr. RAM KUMAR	<b>Client Name</b>	Civil Hospital-P	<b>Specimen Received</b>	22/09/2018
<b>Age/Sex</b>	45/M			<b>Specimen Type</b>	Tissue
<b>Patient ID</b>	011809220218	<b>Client Code</b>	MolQ1681P	<b>Collection Date</b>	22/09/2018
<b>Specimen ID</b>	MOLQ/B-1023-18	<b>Ref. Doctor</b>	DR BALWINDER SINGH	<b>Report Date</b>	25/09/2018

## SURGICAL PATHOLOGY REPORT

### GALL BLADDER.

#### DIAGNOSIS

**CHOLECYSTITIS AND CHOLELITHIASIS.**



#### SPECIMEN

Gall Bladder.

#### GROSS

Received 6.5 x 3.2 cm long gall bladder. Cut section shows stones.


#### Microscopy

1. Section examined shows ulcerative mucosa and Rokitansky Aschoff sinuses with fibrocollagenous tissue.

**Note :** All biopsy specimen will be stored for 15 (fifteen) days, block and slides for 5 (five) years only from the time of receipt at the laboratory. No request, for any of the above, will be entertained after the due date.

#### Reference

- i) Rosai and Ackerman's Surgical Pathology.
- ii) Modern Surgical Pathology.



**Gulshan Yadav, MD**  
Consultant Pathologist