

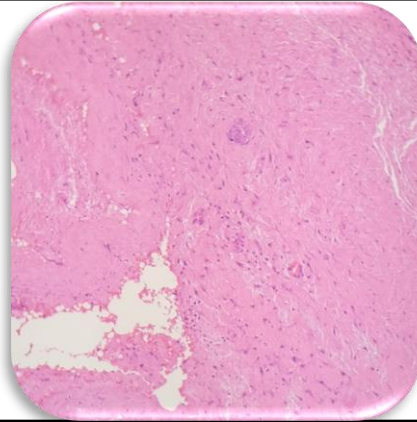
<b>Patient Name</b>	<b>Mr. BHOOP SINGH</b>	<b>Client Name</b>	Pushpanjali Hospital	<b>Specimen Received</b>	21/09/2018
<b>Age/Sex</b>	38/F		(Rewari)	<b>Specimen Type</b>	Tissue
<b>Patient ID</b>	011809210313	<b>Client Code</b>	MolQ1789CM	<b>Collection Date</b>	21/09/2018
<b>Specimen ID</b>	MOLQ/B-1019-18	<b>Ref. Doctor</b>	DR.KULDEEP	<b>Report Date</b>	25/09/2018

## SURGICAL PATHOLOGY REPORT

### ABDOMINAL CAVITY

#### DIAGNOSIS

**NON-SPECIFIC INFLAMMATION**



#### SPECIMEN

Abdominal Cavity

#### GROSSING

Received 1x1cm greyish white tissue piece.

#### Microscopy

1. Section examined shows fibro collagenous Tissue, Muscle Bundle blood vessels and Mature adipose cells with polymorphs and lymphocytes
2. No malignant cells seen.
3. No granuloma seen.

**Note :** All biopsy specimen will be stored for 15 (fifteen)days, block and slides for 5(five) years only from the time of receipt at the laboratory. No request ,for any of the above ,will be entertained after the due date.

#### Reference

- i) Rosai and Ackerman's Surgical Pathology.
- ii) Modern Surgical Pathology

**Gulshan Yadav, MD**  
Consultant Pathologist