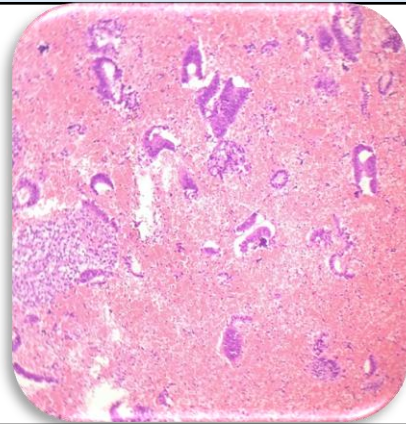


Patient Name	Mrs. RENU	Client Name	Tilak Hospital	Specimen Received	20/09/2018
Age/Sex	50/F	Client Code	MOLQ1087P	Specimen Type	Tissue
Patient ID	011809200293	Ref. Doctor		Collection Date	20/09/2018
Specimen ID	MOLQ/B-1016/18			Report Date	24/09/2018

SURGICAL PATHOLOGY REPORT
ENDOMETRIUM

DIAGNOSIS

PROLIFERATIVE PHASE



SPECIMEN

Endometrium

GROSSING

Received multiple greyish white tissue piece.

Microscopy

1. Section examined shows small endometrial glands having columnar lining epithelium with round to oval nucleus with squamous metaplasia.
2. Stroma shows mononuclear inflammatory cells.
3. No granuloma seen.
4. No malignant cells seen.

Note : All biopsy specimen will be stored for 15 (fifteen) days, block and slides for 5 (five) years only from the time of receipt at the laboratory. No request ,for any of the above ,will be entertained after the due date.

Reference

- i) Rosai and Ackerman's Surgical Pathology.
- ii) Modern Surgical Pathology

Gulshan Yadav, MD
Consultant Pathologist