

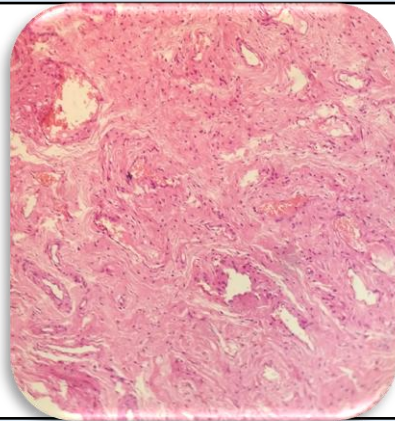
|                     |                |                    |                               |                          |            |
|---------------------|----------------|--------------------|-------------------------------|--------------------------|------------|
| <b>Patient Name</b> | Mr. RAMKISHAN  | <b>Client Name</b> | Pushpanjali Hospital (Rewari) | <b>Specimen Received</b> | 20/09/2018 |
| <b>Age/Sex</b>      | 60/M           |                    |                               | <b>Specimen Type</b>     | Tissue     |
| <b>Patient ID</b>   | 011809200239   | <b>Client Code</b> | MolQ1514P                     | <b>Collection Date</b>   | 20/09/2018 |
| <b>Specimen ID</b>  | MOLQ/B-1014-18 | <b>Ref. Doctor</b> | DR.KULDEEP                    | <b>Report Date</b>       | 25/09/2018 |

## SURGICAL PATHOLOGY REPORT

### GALL BLADDER.

#### DIAGNOSIS

**CHOLECYSTITIS AND CHOLELITHIASIS.**



#### SPECIMEN

Gall Bladder.

#### GROSS

Receive 7x3 cm long gall bladder.


#### Microscopy

1. Section examined shows ulcerative mucosa and Rokitansky-Aschoff sinuses with fibrocollagenous tissue.

**Note :** All biopsy specimen will be stored for 15 (fifteen) days, block and slides for 5 (five) years only from the time of receipt at the laboratory. No request, for any of the above, will be entertained after the due date.

#### Reference

- i) Rosai and Ackerman's Surgical Pathology.
- ii) Modern Surgical Pathology.



**Gulshan Yadav, MD**  
Consultant Pathologist