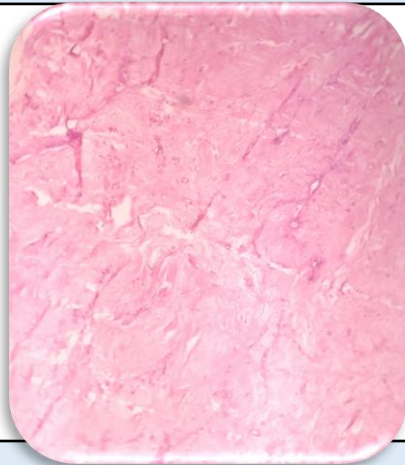


Patient Name	Mrs. NEHA	Client Name	Civil Hospital-P	Specimen Received	19/09/2018
Age/Sex	21/F			Specimen Type	Tissue
Patient ID	011809190273	Client Code	MolQ1681P	Collection Date	19/09/2018
Specimen ID	MOLQ/B-1009-18	Ref. Doctor	DR AMANDEEP	Report Date	22/09/2018

SURGICAL PATHOLOGY REPORT
LEFT FIBROADENOMA BREAST

DIAGNOSIS

BENIGN BREAST LESION



SPECIMEN

Left Fibroadenoma Breast

GROSS

Received 1x1cm greyish white tissue piece.

Microscopy

1. Section examined shows ducts with cuboidal epithelium with small round nucleus surrounded by fibro collagenous tissue.
2. No granuloma seen.
3. No malignant cells seen

Note : All biopsy specimen will be stored for 15 (fifteen)days, block and slides for 5(five) years only from the time of receipt at the laboratory. No request ,for any of the above ,will be entertained after the due date.

Reference

- i) Rosai and Ackerman's Surgical Pathology.
- ii) Modern Surgical Pathology.

Gulshan Yadav, MD
Consultant Pathologist