

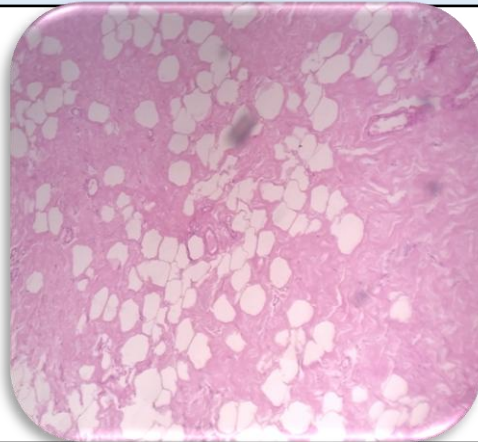
Patient Name	Mrs. MEENA DEVI	Client Name	Civil Hospital-P	Specimen Received	19/09/2018
Age/Sex	40/F			Specimen Type	Tissue
Patient ID	011809190268	Client Code	MolQ1681P	Collection Date	19/09/2018
Specimen ID	MOLQ/B-1002-18	Ref. Doctor	Dr. ALKA SINGH	Report Date	22/09/2018

SURGICAL PATHOLOGY REPORT

LEFT BREAST

DIAGNOSIS

BENIGN BREAST LESION



SPECIMEN

Left Breast

GROSS

Received 9x6x3 cm greyish white tissue piece with adipose tissue.

Microscopy

1. Section examined shows ducts with cuboidal epithelium with small round nucleus surrounded by fibro collagenous tissue.
2. No granuloma seen.
3. No malignant cells seen

Note : All biopsy specimen will be stored for 15 (fifteen)days, block and slides for 5(five) years only from the time of receipt at the laboratory. No request ,for any of the above ,will be entertained after the due date.

Reference

- i) Rosai and Ackerman's Surgical Pathology.
- ii) Modern Surgical Pathology.



Gulshan Yadav, MD
Consultant Pathologist